

Screening esophagus during routine ultrasound: medical and cost benefits

Abd Elrazek M.A. Abd Elrazek^a, Khaled A. Eid^a, Abd Elhalim A. El-Sherif^a, Usama M. Abd El Al^b, Samir M. El-Sherbiny^d and Shymaa E. Bilasy^c

Objective Cost-effectiveness analysis is an approach used to determine the value of a medical care option and refers to a method used to assess the costs and health benefits of an intervention. Upon the diagnosis of liver cirrhosis, the current guidelines recommend that all cirrhotic patients have to be screened for the presence of esophageal varices by endoscopy. In addition, patients with a positive family history of esophageal cancer are screened annually. These approaches place a heavy burden on endoscopy units, and repeated testing over time may have a detrimental effect on patient compliance.

Patients and methods Following the recommendations of a recent study entitled 'Detection of risky esophageal varices using two dimensional ultrasound: when to perform endoscopy', the intra-abdominal portion of the esophagus of 1100 patients was divided into a hepatic group, which included 650 patients, and a nonhepatic group, which included 450 patients, who presented with manifestations of liver diseases and gastrointestinal symptoms, respectively, and were examined using standard two-dimensional ultrasound (US) to evaluate cost effectiveness, standard issues, and medical benefits using conventional US.

Introduction

Healthcare advancements in new drugs or screening and diagnostic tests must show safety and efficacy to be approved for clinical use. However, because of increasing healthcare costs and limited budgets, questions may remain about their value [1]. Esophageal diseases are an important medical concern in developed and developing countries, where neoplasms and esophageal varices are common, respectively. Given the cost and invasive nature of endoscopic screening, there is an interest in the development of a noninvasive predictor for the presence and development of esophageal diseases. Two-dimensional ultrasound (2D US) uses nonionizing radiation to create the image and is associated with no side effects or complications. The use of this method is easy and inexpensive for esophageal screening [2–6]. The ability to observe the intra-abdominal portion of the esophagus with 2D US has been recognized. Esophageal abnormalities, including neoplasms, hiatus hernias, and reflux esophagitis, can be detected in this part of the esophagus. Esophageal varices caused by portal

Results The overall effectiveness analysis of 1100 patients yielded a 41% cost standard benefit calculated to be \$114 760 in a 6-month study.

Conclusion Two-dimensional US can play an important role in screening for esophageal abnormalities, thus saving money and time. The esophagus should be screened during routine conventional abdominal US. *Eur J Gastroenterol Hepatol* 27:8–12 © 2014 Wolters Kluwer Health | Lippincott Williams & Wilkins.

European Journal of Gastroenterology & Hepatology 2015, 27:8–12

Keywords: esophageal neoplasms, esophageal varices, two-dimensional ultrasound

^aDepartment of Tropical, GIT and Hepatology, Al-Azhar Faculty of Medicine, Al-Azhar University, Asiat, Cairo, ^bDepartment of Internal Medicine, Sohag Faculty of Medicine, Sohag, ^cDepartment of Biochemistry, Faculty of Pharmacy, Suez Canal University, Ismailia, Egypt and ^dDepartment of Internal Medicine, Hail General Hospital, Hail, Saudi Arabia

Correspondence to Abd Elrazek M. A. Abd Elrazek, PhD, MD, Department of Tropical Medicine, GIT and Hepatology, Al-Azhar Faculty of Medicine, Asiat 721-572, Cairo, Egypt
Tel: +2 0882180445; fax: +2 0882181194; e-mail: ahmadrazek@gmail.com

Received 7 June 2014 Accepted 23 July 2014

hypertension are usually more prominent in the distal (i.e. abdominal) esophagus [7]. Thus, the intra-abdominal portion of the esophagus should be examined regularly during routine conventional US sessions. This study was established to examine the cost effectiveness and the benefits of 2D US for the detection of esophageal diseases.

Patients and methods

Between January and June 2014, at Al-Azhar University Hospitals and other private hospitals in Egypt and Saudi Arabia, conventional 2D US was performed as a routine standard investigation for 1100 patients aged between 17 and 81 years, 750 men and 350 women. Patients presented with chronic liver disease (hepatic group) or gastrointestinal disorders (nonhepatic group) in the outpatient clinic or hospitalized patients. The hepatic group included 650 patients with a history of chronic liver diseases and the nonhepatic group included 450 patients who presented with gastrointestinal tract disturbances of irritable bowel syndrome, gastroesophageal reflux disease, hiatus hernia, esophageal spasm, or other disorders. For each patient, we applied a convex 2D US probe

All supplementary digital content is available directly from the corresponding author.

to the midline (epigastric region) to examine the lower esophagus. The thicknesses of the anterior and posterior walls of the intra-abdominal esophagus were measured during shallow respiration, and irregularities of the inner surface were assessed. All patients were followed up for 6 months by 2D US. Patients showing increased esophageal wall thicknesses of more than 4.2 mm underwent diagnostic upper endoscopy to evaluate esophageal abnormalities. The average cost of each upper endoscopy was calculated for \$300 and the average cost for each 2D US was \$40. These average costs may differ according to other countries/situations.

Statistical analysis

Statistical analysis was used to perform a cost-effectiveness comparison between all patients requiring diagnostic endoscopy and selected patients by 2D US conventional examination using the one-way analysis of variance test with post-hoc multiple two-group comparisons. All statistical calculations were carried out using computer program SPSS version 15 for Microsoft Windows (Statistical Package for the Social Sciences; SPSS Inc., Chicago, Illinois, USA).

Results

In this study, we examined 1100 patients, divided into two groups: hepatic and nonhepatic (Fig. 1). In the hepatic group and during the 6-month follow-up period by 2D US, 356/650 (55%) patients underwent routine diagnostic endoscopy for variceal screening because of increased esophageal wall thickness more than 4.2 mm and 199/356 (56%) patients needed prophylactic band ligation endoscopic therapy, whereas the other 157/356 patients did not require the band ligation according to endoscopic evaluation criteria for risky varices. The rest of the patients, 294/650, showed normal esophageal wall thickness and continued to be monitored by routine US. In the nonhepatic group, only 14/450 (3%) patients underwent upper endoscopy for various reasons, whereas all the other patients continued to be monitored by 2D US. The overall expense for all cases who required diagnostic endoscopy for screening of esophageal varices should be \$195 000; however, the total expense for patients who only required diagnostic endoscopy by 2D US was \$80 240 (41%), cost-effectiveness standard benefit (Fig. 2). Although there was no significant cost efficacy in the nonhepatic group, screening of the esophagus was useful as a primary survey for those with esophageal neoplasms and esophageal varices. 2D US is a valuable tool in identifying patients with increased esophageal wall thickness at a higher risk for developing esophageal varices ($P < 0.001$).

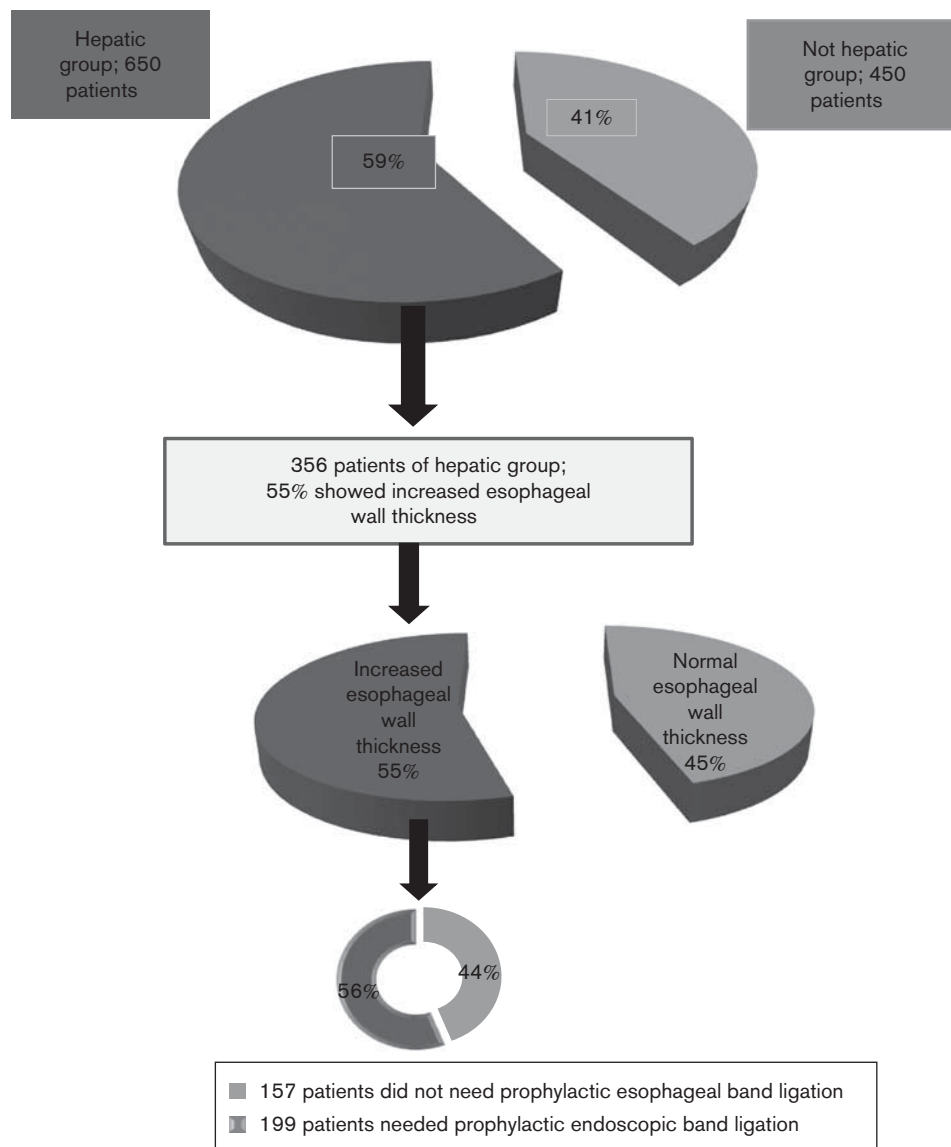
Discussion

The epidemiology, etiologic factors, and clinical manifestations of esophageal diseases are important worldwide. Routinely, a noninvasive diagnosis of certain esophageal

disorders is preferred to invasive endoscopies, especially in certain societies, where esophageal neoplasms and/or esophageal varices are the predominant cause of morbidities and mortalities. For example, in the USA an estimated 18 170 cases of esophageal cancer were diagnosed in 2013, and 15 450 deaths are expected from the disease [8]. Worldwide, an estimated 482 300 new esophageal cancer cases and 406 800 deaths occurred in 2008 [9,10]. In the same context, almost half of the patients with hepatic cirrhosis have esophageal varices, and one-third of all patients with varices will develop variceal hemorrhage, a major cause of morbidity and mortality in patients with liver cirrhosis. The risk of hemorrhage has been related to the size and appearance of the varices as well as the degree of hepatic dysfunction [11,12]. According to the American Association for the Study of Liver Diseases guidelines (AASLD), all cirrhotic patients should undergo screening endoscopy for varices upon the diagnosis of cirrhosis to identify high-risk patients. Repeated endoscopies lead to an economic burden, involve a degree of invasiveness and discomfort to patients, and place a heavy burden on endoscopy units. The Baveno V consensus guidelines recommend primary prophylaxis with nonselective β -blockers for patients with small varices with red wale marks or those patients with Child C cirrhosis. Following these, patients with small varices without signs of increased risk for hemorrhage (red wale marks) or Child C cirrhosis can be considered for treatment with nonselective β -blockers only. The guidelines also recommend that patients with medium or large varices (grades III, IV) be treated with a combination therapy of β -blockers and endoscopic variceal band ligation [13–17].

Recently, our group assessed the degree of esophageal varices by 2D US using data mining statistical computed analysis in 673 patients, which shed light on significant factors for each disease condition [7]. A major challenge of biomedical data mining is to make these systems useful for biomedical researchers [18,19]. To follow-up our previous finding, we designed this study to confirm the value of 2D US and assess the cost effectiveness of 2D US as a screening tool for esophageal varices. Indeed, we observed that 2D US is a valuable tool to identify patients with increased esophageal wall thickness. The use of 2D US as a preliminary screening tool reduced the overall expenses by 41% versus opting for the endoscopy. Each patient was screened by 2D US of the lower esophagus for esophageal wall thickness and irregularities. Using the left lobe of the liver as an acoustic window, we could observe the lower esophagus (intra-abdominal portion, 3.2–4.2 mm) as separate anterior and posterior walls between the left lobe of the liver and the aorta (Fig. 3); the anterior and posterior walls are hypoechoic, whereas the lumen is hyperechoic. Thus, US examination of the intra-abdominal esophagus should be the screening test of choice in the evaluation of cirrhotic patients with esophageal varices to decide the best time

Fig. 1



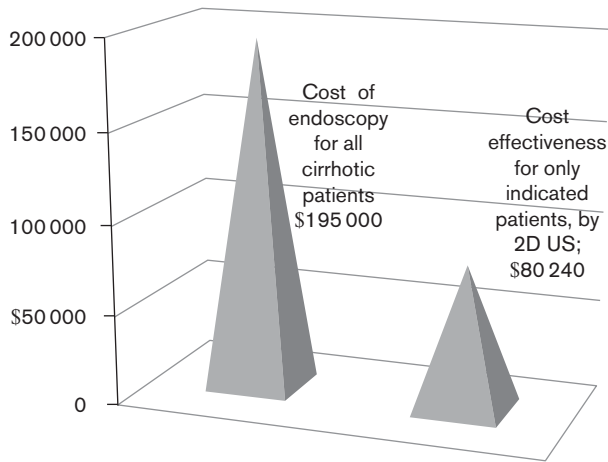
Flowchart of all the patients in the study; (top): whole hepatic 59% and nonhepatic 41%. Only 356 patients, 55% of the hepatic group, showed increased esophageal wall thickness (middle). 199/356 patients (56%), needed prophylactic esophageal band ligation (bottom) ($P < 0.001$).

for interventional therapeutic endoscopy and for other patients with esophageal abnormalities detected by 2D US to be referred for diagnostic upper endoscopy.

In this study, we performed US in 1100 patients by applying a convex 2D US probe to the midline (epigastric region), divided into hepatic and nonhepatic groups. Following patients using conventional US was helpful in monitoring esophageal wall thickness in all disease progression and regression. In the hepatic group, 356/650 (55%) patients showed increased esophageal wall thicknesses and of these patients, 199/356 (56%) needed prophylactic endoscopic band ligation. In the nonhepatic

group (450 patients), two patients showed a bulk-like appearance in the anterior esophageal wall with a normal posterior wall by US examination. Upper endoscopy indicated a mass in the anterior wall of the lower esophagus and biopsies showed adenocarcinoma of the esophagus. One of them was an operable young patient, and was subjected to surgical resection; the other one was an inoperable 75-year-old man who died 5 weeks after diagnosis. Another 12 patients who did not improve on therapy in the nonhepatic group underwent diagnostic endoscopy with or without manometric study because of different causes of esophageal disorders, for example, lower end esophagitis, esophageal spasm, hiatus hernia,

Fig. 2



Using 2D US was very helpful in determination of esophageal wall thicknesses in cirrhotic patients, resulting in a saving of \$114 760 in a 6-month study of 650 patients. 2D US, two-dimensional ultrasound.

or/and Barrett’s esophagus. Overall, 2D US played an important role in screening for esophageal abnormalities in both hepatic and nonhepatic groups. In addition, the overall cost-effectiveness benefit was 41.1% for all 1100 randomized patients screened for esophageal wall thicknesses (\$114 760).

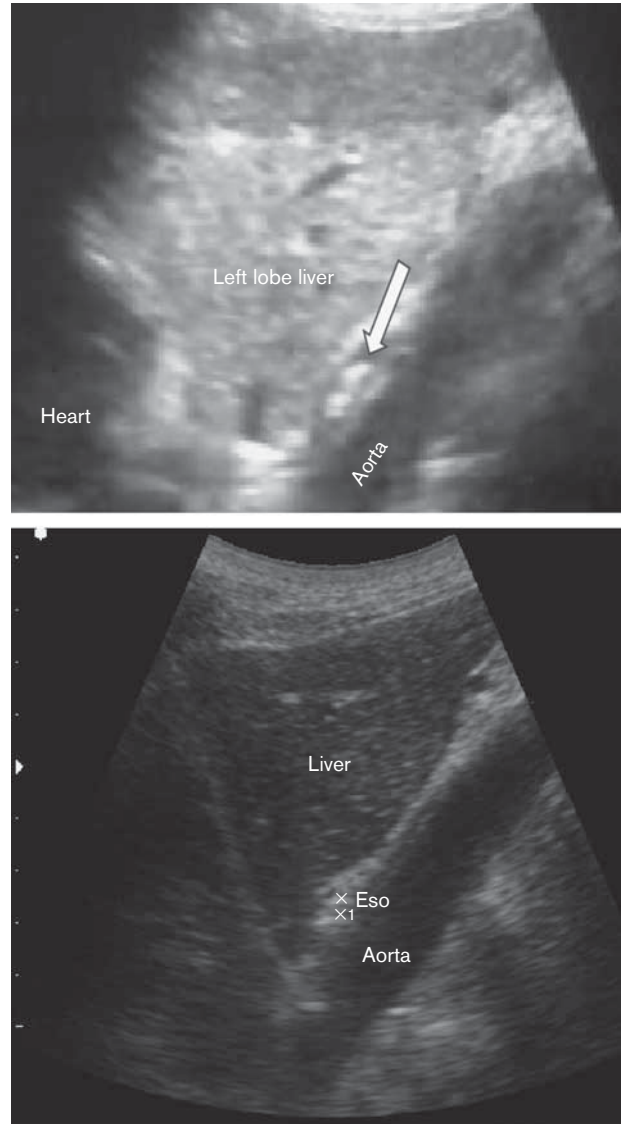
Conclusion

Screening the esophagus using noninvasive 2D US proved to be a helpful tool in saving time and money without invasive complicated morbidities. In addition, screening of the esophagus could be helpful in organ transplantation, where upper endoscopy is mandatory for evaluation of the presence of esophageal varices or neoplasms, especially in the field of living-donor liver transplantation. Therefore, 2D US screening should be preferred to upper endoscopy to avoid complications, especially in those patients receiving high doses of immunosuppressant drugs with comorbidities. Although upper gastrointestinal endoscopy remains the gold standard for the diagnosis of esophageal abnormalities in both cirrhotic and noncirrhotic patients, despite its limitations, other noninvasive biochemical and radiologic parameters are not sufficiently accurate to replace endoscopic screening in many situations worldwide. We suggest that 2D US, a simple, easy, portable, and inexpensive tool, should be used routinely to screen for esophageal abnormalities in both hepatic and nonhepatic groups.

Study limitations

- (1) Cost-effectiveness analysis could differ from center to center and from one society to another.
- (2) Clinical experience played a major role in assessing the information mentioned above; furthermore, our

Fig. 3



Intra-abdominal portion of the esophagus (arrow). The best sonographic appearance of the esophagus is between the left lobe of the liver (acoustic window) and the abdominal aorta. X to X1 is the thickness of the anterior esophageal wall.

results should be confirmed using more evidence-based criteria according to the economic status of each society. All values reported are from a scientific point of view.

Acknowledgements

Conflicts of interest

There are no conflicts of interest.

References

- 1 American College of Physicians. Information on cost-effectiveness: an essential product of a national comparative effectiveness program. *Ann Intern Med* 2008; **148**:956–961.

- 2 Garcia-Tsao G, Sanyal AJ, Grace ND, Carey W. Practice Guidelines Committee of the American Association for the Study of Liver Diseases; Practice Parameters Committee of the American College of Gastroenterology. Prevention and management of gastroesophageal varices and variceal hemorrhage in cirrhosis. *Hepatology* 2007; **46**:922–938.
- 3 De Franchis R, Baveno V Faculty. Revising consensus in portal hypertension: report of the Baveno V consensus workshop on methodology of diagnosis and therapy in portal hypertension. *J Hepatol* 2010; **53**:762–768.
- 4 Baquet CR, Commiskey P, Mack K, Meltzer S, Mishra SI. Esophageal cancer epidemiology in blacks and whites: racial and gender disparities in incidence, mortality, survival rates and histology. *J Natl Med Assoc* 2005; **97**:1471–1478.
- 5 Edge SB, Byrd DR, Compton CC, Fritz AG, Greene FL, Trotti A. *American joint committee on cancer staging manual*. 7th ed. New York: Springer; 2010.
- 6 Kishimoto R, Chen M, Ogawa H, Wakabayashi MN, Kogutt MS. Esophageal varices: evaluation with transabdominal US. *Radiology* 1998; **206**:647–650.
- 7 Abd Elrazek MA, Mahfouz H, Afifi M, Nafady M, Fathy Ael W, El Azeem KA, et al. Detection of risky esophageal varices by two-dimensional ultrasound: when to perform endoscopy. *Am J Med Sci* 2014; **347**:28–33.
- 8 Barbour AP, Jones M, Gonen M, Gotley DC, Thomas J, Thomson DB, et al. Refining esophageal cancer staging after neoadjuvant therapy: importance of treatment response. *Ann Surg Oncol* 2008; **15**:2894–2902.
- 9 Nomura M, Shitara K, Kodaira T, Hatooka S, Mizota A, Kondoh C, et al. Prognostic impact of the 6th and 7th American Joint Committee on Cancer TNM staging systems on esophageal cancer patients treated with chemoradiotherapy. *Int J Radiat Oncol Biol Phys* 2012; **82**:946–952.
- 10 Greene FL, Page DL, Fleming ID, Fritz AG, Balch CM, Haller DG, Morrow M. *American joint committee on cancer staging manual*. 6th ed. New York: Springer-Verlag; 2002.
- 11 D'Amico G, de Franchis R. Cooperative Study Group. Upper digestive bleeding in cirrhosis. Post-therapeutic outcome and prognostic indicators. *Hepatology* 2003; **38**:599–612.
- 12 Rye K, Scott R, Mortimore G, Lawson A, Austin A, Freeman J. Towards noninvasive detection of oesophageal varices. *Int J Hepatol* 2012; **2012**:343591.
- 13 Vlachogiannakos J, Goulis J, Patch D, Burroughs AK. Review article: primary prophylaxis for portal hypertensive bleeding in cirrhosis. *Aliment Pharmacol Ther* 2000; **14**:851–860.
- 14 Merli M, Nicolini G, Angeloni S, Rinaldi V, De Santis A, Merkel C, et al. Incidence and natural history of small esophageal varices in cirrhotic patients. *J Hepatol* 2003; **38**:266–272.
- 15 Aslam N, Waters B, Riely CA. Intraoperative rupture of ectopic varices: two case reports and a review of literature. *Am J Med Sci* 2008; **335**:160–162.
- 16 Santos MM, Tolentino LH, Rodrigues RA, Nakao FS, Rohr MR, de Paulo GA, et al. Endoscopic treatment of esophageal varices in advanced liver disease patients: band ligation versus cyanoacrylate injection. *Eur J Gastroenterol Hepatol* 2011; **23**:60–65.
- 17 Liangpunsakul S, Ulmer BJ, Chalasani N. Predictors and implications of severe hypersplenism in patients with cirrhosis. *Am J Med Sci* 2003; **326**:111–116.
- 18 Abd Elrazek AE, Mahfouz HM, Metwally AM, El-Shamy AM. Mortality prediction of nonalcoholic patients presenting with upper gastrointestinal bleeding using data mining. *Eur J Gastroenterol Hepatol* 2014; **26**:187–191.
- 19 Grossi E, Buscema M. Introduction to artificial neural networks. *Eur J Gastroenterol Hepatol* 2007; **19**:1046–1054.